

A Case of Low Phosphorus Osteomalacia in a Young Woman

WANG XING, ZHANG TAO*

The First Affiliated Hospital of Xinjiang Medical University, Urumqi, Xinjiang, 830054, China

Abstract: *Hypophosphorous osteomalacia (HO) is a rare metabolic disease. Due to hypophosphatemia and insufficient production of active vitamin D, the bone matrix can not be mineralized normally. Its clinical symptoms are atypical. It is generally manifested in bone pain and muscle weakness in different parts. With the progress of the disease, it is very easy to have osteoporosis, pathological fracture, bone deformity and damage to the function of other organs of the whole body. The etiology can be divided into primary and secondary according to the pathogenesis [1]. The primary is often caused by genetic factors, which can be divided into X-linked dominant low phosphorus osteomalacia (XLH) and autosomal dominant low phosphorus osteomalacia (ADHR). The secondary cause can be low phosphorus osteomalacia (TIO) caused by exposure to some drugs or heavy metals and tumors. This disease is rare in clinic, so clinicians have insufficient understanding of the disease and are prone to missed diagnosis or misdiagnosis. This paper reports a case of adult female with low phosphorus osteomalacia. The diagnosis, treatment and treatment are analyzed and discussed in order to provide reference for clinic.*

Keywords: *fracture, low phosphorus, metabolic disease, gene*

1. Introduction

The early symptoms of low phosphorus osteomalacia are not typical. Severe cases have pain and tenderness in the spine, pelvic load-bearing joints and proximal joints of limbs. Sometimes they can spread all over the joints of the whole body, and the muscles are weak. Because the vertebral body is compressed, the height can be shortened. Primary Hypophosphorous osteomalacia often occurs in childhood. X-linked dominant inheritance is the most common genetic mode of the disease [2, 3], which is related to phec gene mutation. This gene is involved in the degradation of FGF-23, which leads to the accumulation of FGF-23 in the body and the disorder of blood phosphorus metabolism [4]. Secondary Hypophosphorous osteomalacia is mostly caused by tumor. Tumor related Hypophosphorous osteomalacia (TIO) is caused by the excessive production of FGF-23 in tumor [5, 6], acting on proximal renal tubules, inhibiting phosphate reabsorption and hydroxylation of 25 hydroxyvitamin D, resulting in a series of clinical changes.

2. Materials and methods

The patient, female, 32 years old, was admitted to the hospital with the main complaint of "intermittent multi joint pain for 12 years". Since 2010, the patient has no obvious inducement: hip joint, knee joint and lumbar pain with general fatigue. After the activity is obvious, she went to the hospital and was preliminarily diagnosed as "osteoporosis". In the treatment, she was given vitamin D drops, calcium tablets and Fosamax (AlendronateSodiumTablets) symptomatic treatment. After the condition improves, she was discharged from the hospital and stopped taking medicine after discharge. In June, 2020, due to the pain of the right thigh and limited movement when squatting, the examination showed that there were multiple fractures of the femoral shaft and fibula on both sides, and the patients were given conservative treatment with plaster external fixation. After that, the patient has been suffering from intermittent joint pain and limited movement, so she was treated in our hospital. In the past, there was no previous operation except fracture operation. Admission physical examination: no abnormality was found in heart, lung and abdomen. Special physical examination: no deformity in limbs, no redness,

*email: zhang1tao3@163.com

swelling and tenderness in joints, no deformity in spine, no tenderness and buckle pain in spinous process, and normal range of motion. There is no varicose vein, ulcer or edema in the lower limbs, and the movement of both lower limbs is limited. Improve laboratory examination tips: potassium: 3.09 (3.5-5.1mmol / L); Sodium 145.84 (137-145 mmol / L); Chlorine: 115 (98-107 mmol / L); Calcium 1.34 (2.1-2.55 mmol / L); Magnesium 0.78 (0.7-1.0mmol / L); Inorganic phosphorus 0.39 (0.81-1.45mmol / L); Creatinine 28.76 (46-92 mmol / L); Alkaline phosphatase 766 (38-126mmol / L); Three items of bone metabolism: 25 hydroxyvitamin d < 7.5nmol/L; Osteocalcin: 64.71ng/mL; Parathyroid hormone: 38.20pmol / L; Tumor markers: cytokeratin 19 fragment 2.62 (0-2.08 ng / mL); Carbohydrate antigen CA153 was 30.90 (0-20u / mL), human leukocyte antigen B27 (HLA-B27) and rheumatoid factor were normal. Due to the patient's multiple joint pain, the whole-body X-ray examination was carried out. Bilateral partial ribs, bilateral upper and lower branches of pubis, bilateral femurs and bilateral tibiofibular fractures, pelvic deformation and osteoporosis were seen. As shown in Figure 1, bone mineral density suggests: severe osteoporosis, as shown in Figure 2.

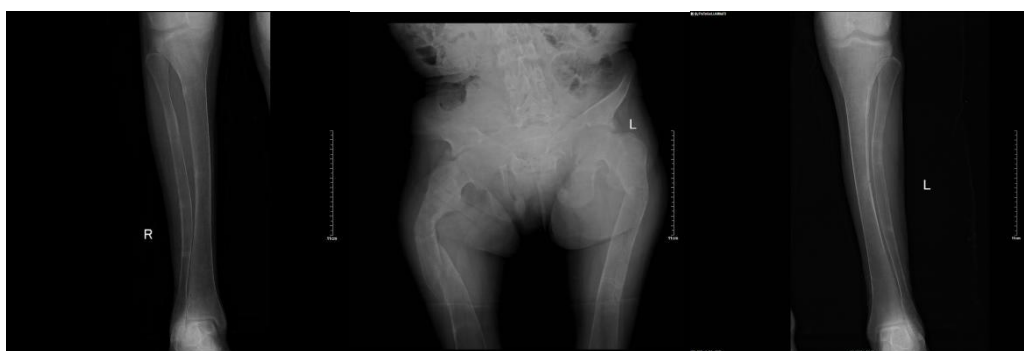

Figure 1. X-ray of whole body bone and joint

(This is the result of plain film scan of part of the patient's bone, showing pelvic deformation and multiple fractures of femur and bilateral tibiofibula)

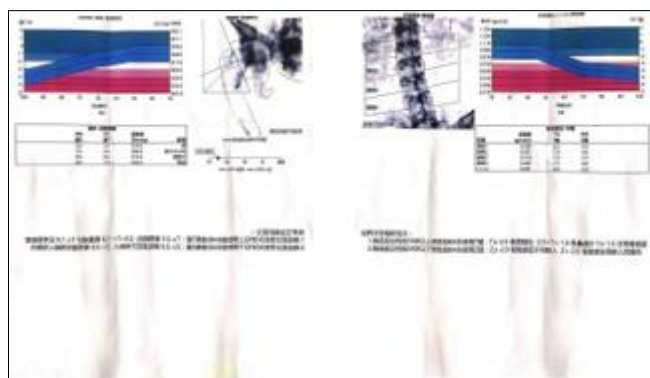


Figure 2. Bone mineral density measurement

(The measurement of bone mineral density in our hospital suggests severe osteoporosis)

After further parathyroid ECT (Emission Computed Tomography), no abnormal uptake of radioactive tracer was found. Combined with the results of serum thyroid function examination, parathyroid diseases were excluded (Figure 3).




Figure 3. Parathyroid ECT (Emission computed tomography)

The whole body bone ect results were normal, and the possibility of neoplastic diseases was excluded (Figure 4).

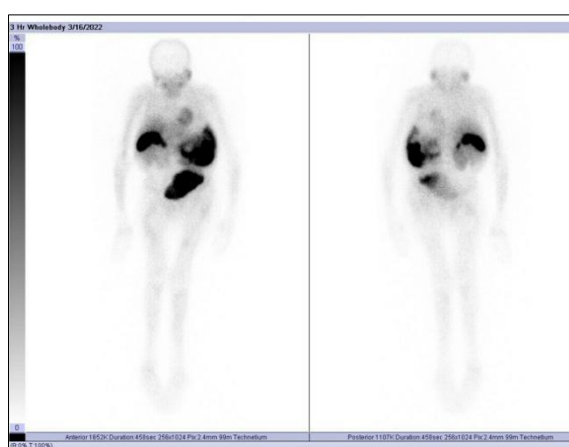


Figure 4. Whole body bone scan

After eliminating the common causes that may lead to low phosphorus, we gave neutral phosphate preparation in treatment, which indicated osteoporosis according to bone mineral density, supplemented by oral administration of calcium Erqi and calcitriol. The patient came to our hospital for outpatient follow-up three months after discharge, which showed that the level of blood phosphorus increased and the symptoms of bone pain improved.

3. Results and discussions

The young female patient was diagnosed with low phosphorus osteomalacia with bone pain, multiple fractures, lower limb mobility disorder, osteoporosis and low blood phosphorus as the main clinical manifestations. After excluding the diseases related to low blood phosphorus and drug factors, the disease was first found and reported in 1937 [7]. The causes of the disease are worth exploring. For adult type low phosphorus osteomalacia, the acquired factors should be considered, for example: (1) vitamin D intake is insufficient or metabolic disorder; second, treatment of hepatitis B virus long-term use of antiviral drugs [8]; renal tubular acidosis and glomerulonephritis; tumor caused hypo phosphoremia (TIO) [9]. After definite diagnosis, the patient was given neutral phosphate treatment. After several months of oral phosphorus treatment, the patient's blood phosphorus increased compared with the previous one. After the clinical symptoms were relieved, the patient was discharged with medicine. Due to the patient's economic reasons, the relevant genetic examination was not carried out, and the root cause of the disease was not found. In the past, it was difficult to diagnose and treat this disease related to gene sequence due to limited understanding, but now with the understanding of the pathogenesis of the disease, we found that fibroblast growth factor 23 (FGF23) [10] plays an important role in regulating phosphorus and vitamin metabolism. FGF23 is encoded on FGF-23 gene located on chromosome 12,



which can reduce the level of serum 1,25 dihydroxyvitamin D and inhibit the reabsorption of phosphate by the kidney, it leads to hypophosphatemia and metabolic bone disease, and plays a suggestive role in the diagnosis of TIO. According to relevant literature reports, TiO is caused by some slow-growing and typical benign phosphourine mesenchymal tumors (PMT) [11], which can occur in any part of the body, soft tissue and bone. Locating these small tumors is the key to treatment. Medical history, physical examination and relevant imaging examination are particularly important. For the treatment of TiO, the latest research progress shows that [12], surgical resection is generally the first choice, Patients without metastasis generally have a good prognosis. When patients are unwilling or do not meet the surgical conditions, radiofrequency, cold ablation and ethanol ablation can be used as adjuvant therapy.

There are many causes leading to osteomalacia. At the beginning, the disease was also misdiagnosed as osteoporosis and underwent surgical treatment for multiple fractures. However, if the cause is not found, only symptomatic treatment can not fundamentally solve the patient's pain. Therefore, it is very important to clarify the cause. The main treatment of the disease is oral neutral phosphate preparation and calcitriol replacement treatment [13]. The dose of phosphate preparation should be 15-60mg/kg, oral 2-3 times a day, the initial dose of calcitriol is 0.25ug/d, during which the blood calcium level can be monitored regularly. Generally, the dose of 0.5-1mg per day for adults is sufficient. However, long-term oral administration of phosphorus mixture is easy to lead to hyperparathyroidism. Blood calcium, blood phosphorus and renal function should be monitored at the same time to keep blood calcium and blood phosphorus at the normal bottom line, so as to avoid complications such as renal failure and renal calcification.

4. Conclusions

Because this disease is rare, it is easy to be confused with simple fracture or other diseases and easy to be misdiagnosed. When we encounter patients with skeletal dysplasia, we should think of metabolic diseases such as low phosphorus osteomalacia, combined with a series of laboratory biochemical examination, imaging and even chromosome examination to improve the detection rate. With the in-depth understanding of various diseases and the emergence of new treatment methods, it is believed that more and more patients can receive timely and effective treatment.

References

1. WHITE K.E., LARSSON T.E., ECONS M.J., The roles of specific genes implicated as circulating factors involved in normal and disordered phosphate homeostasis: frizzled related protein-4, matrix extra-cellular phosphoglycoprotein, and fibroblast growth factor 23. *Endocr Rev*, 2006 May, 27(3), 221-41. [doi: 10.1210/er.2005-0019](https://doi.org/10.1210/er.2005-0019). Epub 2006 Feb 7. PMID: 16467171
2. ZHONGYUAN, HUANGYUANYUAN, TANG LIZHI, CHENDECAI, LU CHUNYAN, Tumor related hypophosphatemia in adults: a case report [j] *Chinese Journal of osteoporosis*, 2020, 26(08), 1175-1179
3. CARPENTER T.O., WHYTE M.P., IMEL E.A., BOOT A.M., HÖGLER W., LINGLART A., PADIDELA R., VAN'T HOFF W., MAO M., CHEN C.Y., SKRINAR A., KAKKIS E., SAN MARTIN J., PORTALE A.A., Burosumab Therapy in Children with X-Linked Hypophosphatemia. *N Engl J Med*. 2018 May 24, 378(21), 1987-1998, [doi: 10.1056/NEJMoa1714641](https://doi.org/10.1056/NEJMoa1714641). PMID: 29791829
4. TIEFENBACH M., SCHEEL M., MAIER A., GEHLEN M., SCHWARZ-EYWILL M., WERNER M., SIEBERS-RENELT U., HAMMER M., Osteomalazie - Klinik, Diagnostik und Therapie [Osteomalacia-Clinical aspects, diagnostics and treatment]. *Z Rheumatol*, 2018 Oct, 77(8):703-718, German, [doi: 10.1007/s00393-018-0510-x](https://doi.org/10.1007/s00393-018-0510-x). PMID: 30097703
5. FRANK F.A., GERBER L., CORNELIUS A., BAUMHOER D., KRIEG A.H., FGF-23 transmitted tumor - induced hypophosphatemic osteomalacia: A rare case of a young woman with recurrent fractures and review of the literature. *J Bone Oncol*, 2022 Jan 29, 33, 100413 [doi: 10.1016/j.jbo.2022.100413](https://doi.org/10.1016/j.jbo.2022.100413). PMID: 35169537; PMCID: PMC8829074



6. CARTER J.M., ERICKSON L.A., An Adult Male with Hypophosphatemic Osteomalacia, *Mayo Clin Proc.* 2016 Jun;91(6):e81-2. doi: [10.1016/j.mayocp.2016.02.022](https://doi.org/10.1016/j.mayocp.2016.02.022). PMID: 27261876
7. ALBRIGHT F., BUTLER A.M., BLOOMBERG E., Rickets resistant to vitamin D therapy, *J Clin Dis Child*, 1937, 54, 529-547
8. WOO E., KUMBHARE D., WINSTON P., Incapacitating pain from Tenofovir Induced Hypophosphatemic Osteomalacia in a Hemophilia Patient - A Case Report. *Can J Pain.* 2020 Dec 14, 4(1), 287-291, doi: [10.1080/24740527.2020.1838890](https://doi.org/10.1080/24740527.2020.1838890). PMID: 33987506; PMCID: PMC7951154
9. PARAMBA F., SILAS M., MASOODI N., BENJAMIN S., PALAKI J.A., Hypophosphatemic Osteomalacia in a Young Adult. *Cureus.* 2021 Mar 4;13(3):e13697 doi:[10.7759/cureus.13697](https://doi.org/10.7759/cureus.13697). PMID: 33833917; PMCID: PMC8019330
10. CARTER J.M., ERICKSON L.A., An Adult Male with Hypophosphatemic Osteomalacia. *Mayo Clin Proc.* 2016 Jun;91(6):e81-2. doi: [10.1016/j.mayocp.2016.02.022](https://doi.org/10.1016/j.mayocp.2016.02.022). PMID: 27261876
11. FLORENZANO P., HARTLEY I.R., JIMENEZ M., ROSZKO K., GAFNI R.I., COLLINS M.T., Tumor-Induced Osteomalacia. *Calcif Tissue Int.* 2021 Jan, 108(1), 128-142 doi: [10.1007/s00223-020-00691-6](https://doi.org/10.1007/s00223-020-00691-6). Epub 2020 Jun 5. PMID: 32504138
12. YIN Z., DU J., YU F., XIA W., Tumor-induced osteomalacia. *Osteoporos Sarcopenia.* 2018 Dec, 4(4), 119-127 doi: [10.1016/j.afos.2018.12.001](https://doi.org/10.1016/j.afos.2018.12.001). Epub 2018 Dec 12. PMID: 30775554; PMCID: PMC6372818
13. TIEFENBACH M., SCHEEL M., MAIER A., GEHLEN M., SCHWARZ-EYWILL M., WERNER M., SIEBERS-RENELT U., HAMMER M., Osteomalazie - Klinik, Diagnostik und Therapie [Osteomalacia-Clinical aspects, diagnostics and treatment], *Z Rheumatol*, 2018 Oct, 77(8), 703-718, German, doi: [10.1007/s00393-018-0510-x](https://doi.org/10.1007/s00393-018-0510-x). PMID: 30097703

Manuscript received: 2 .04. 2022